

# THE ROLE OF MRI IN ABDOMINAL IMAGING

by **Dr Andrew Stuart**

## THE ROLE OF MRI IN ABDOMINAL IMAGING

The use of MR in abdominal imaging has made huge advances in recent years related largely to shorter breath hold/ breathing independent sequences achieved with newer technology MRI scanners.

The major advantages of MR over CT in the abdomen include better intrinsic soft tissue contrast and the lack of ionizing radiation. The latter is especially important in the younger population, pregnant women and when serial examinations are contemplated such as in monitoring or screening for disease.

When deciding on the appropriate imaging study, historically diagnostic accuracy and cost have been the main drivers. With increasing concerns regarding radiation the new imaging paradigm has shifted towards diagnostic accuracy and patient safety ahead of cost. By following a traditional approach by starting with the perceived least costly test (ultrasound-CT-MRI) the overall cost may increase as apposed to a single most sensitive test.

Liver pathology has been shown to be more accurately assessed with MR with the added benefit of no radiation. Studies have shown superior detection and characterisation of abnormalities by MR compared to both ultrasound and CT.<sup>1</sup>

Perhaps the major strength of MR is in the imaging of biliary and pancreatic ducts (MRCP or magnetic resonance cholangiopancreatography) where the inherent contrast of the fluid filled ducts provides superb anatomical and pathological delineation. While ultrasound is excellent for assessing the gallbladder and intrahepatic ducts, visualisation of the distal CBD, pancreas and the pancreatic ducts is often limited due to bowel gas and patient adiposity. If the ultrasound fails to provide adequate information, ERCP (the main alternative), provides higher spatial resolution and simultaneous ability for intervention but

is associated with up to a 5% iatrogenic complication rate (most noticeably pancreatitis) and involves radiation. This has resulted in a shift to diagnostic MRCP prior to ERCP consideration. There is now a rebate for biliary and pancreatic imaging (item 63482) requiring specialist referral (as do all MR rebates) for 'suspected biliary or pancreatic pathology. This examination will generally provide coverage of the liver and other upper abdominal organs as well.

Renal, adrenal and splenic MR imaging demonstrates slighter greater diagnostic accuracy than CT.<sup>2,3</sup> A rebate is available for adrenal imaging for an adrenal mass in a patient with a malignancy which is otherwise resectable (item 63461). A notable exception to this MR superiority is imaging for renal calculi in which both ultrasound (renal stones only) and to a greater degree CT (renal and ureteric stones) are more sensitive tests.

In the bowel an expanding role for MR is developing. Recently there has been the introduction of a Medicare rebate for rectal cancer staging prior to surgery (item 63476) which provides more accurate local staging than CT. MR is also excellent for anal fistulas in defining the relationship of the fistula to the anal sphincteric complex.

Other roles of MR in the pelvis include the assessment of pelvic floor prolapse, workup for fibroid embolisation, renal artery stenosis assessment and staging prostate and gynaecological cancers. A specialist referred Medicare rebate is available for staging cervical cancer (1B or greater) (item 63470). In fact MR can be used for assessing numerous intraperitoneal or retroperitoneal masses. It is worth remembering a Medicare rebate applies in persons U16 for the evaluation of a pelvic or abdominal mass (item 63440).

In summary it needs to be remembered that MR provides a high detection and characterisation rate in the abdomen, involves no ionizing radiation and does not

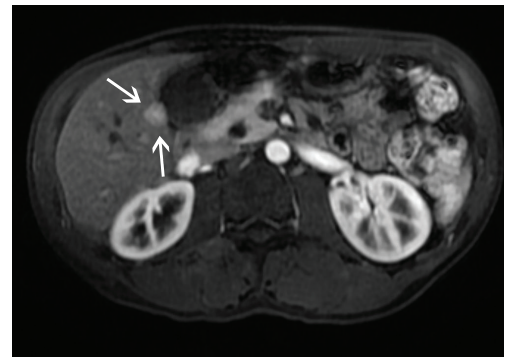


Figure 1. Small hepatocellular carcinoma detected on contrast enhanced MRI not seen on ultrasound or CT.

require iodine containing contrast. Aside from strict contra-indications like cardiac pacemakers, the major hindrances to its usage include relative cost due to the limited number of Medicare rebates, accessibility (especially from a general practitioner perspective), and the lack of awareness of its superiority to both ultrasound and CT in imaging many of the abdominal and pelvic organs and structures.

## REFERENCES

- 1 Noone et al. Abdominal Imaging Studies: Comparison of diagnostic accuracies resulting from U/S, CT and MRI in same individual. *MR Imaging* 22(2004) 19-24
- 2 Jose et al. When should MRI be used? *Clin Gastroenterology and Hepatology* 2008;6:610-615
- 3 Low et al. Extrahepatic abdominal imaging in patients with malignancy: Comparison of MR and CT with subsequent surgical correlation. *Radiology* March 1999(210) 625-632

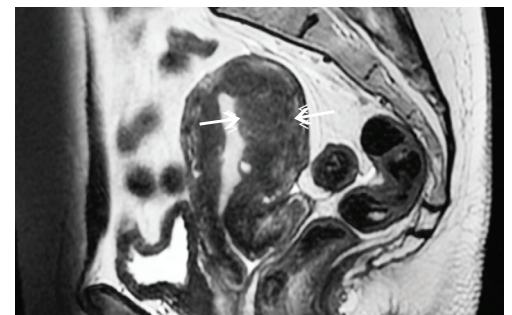


Figure 2. Sagittal MRI image showing thickened junctional zone in adenomyosis in workup for uterine fibroid embolisation for menorrhagia



**DR ANDREW STUART**

MBBCh (Wits),  
FFRad (D) SA, FRCR  
(London), FRANZCR

*Diagnostic and MSK Radiologist  
Head of MRI, San Radiology  
Dr Stuart may be contacted on  
(02) 9487 9850 or 9980 3882.*