

San RADIOLOGY UPDATE

RENAL ARTERY STENOSIS: DIAGNOSIS AND INTERVENTION

by Dr Eisen Liang

Hypertensive disease affects 10% of the population with 2.1 million Australians diagnosed as hypertensive. Each year 3% of the adult population develop hypertensive disease.

Renal Artery Stenosis (RAS) is a secondary cause in 4 - 5% of the population with hypertension. Clinical predictors include: onset of hypertension before age 30 or after age 60, difficult to control hypertension (Box 1), development of renal impairment with ACE inhibitor or angiotensin II blocker, presence of coronary and peripheral arterial disease, and flash pulmonary edema (Box 2).

BOX 1: DIFFICULT TO CONTROL HYPERTENSION

• **Accelerated hypertension:** sudden deterioration of previously controlled hypertension.

• **Resistant hypertension:** systolic blood pressure cannot be reduced to less than 140/90 mm Hg in patients on triple drug regimen.

• **Malignant hypertension:** sudden onset of severe hypertension with end-organ damage, such as LVH, CHF, visual or neurologic disturbance, and/or grade III/IV retinopathy.

BOX 2: FLASH PULMONARY EDEMA

(Aka: Cardiac disturbance syndrome)

• Is defined as recurrent pulmonary edema that is not believed to be secondary to impaired cardiac function;

• Seen in the setting of bilateral renal artery stenosis (RAS) or unilateral stenosis of the renal artery to a solitary kidney.

Renal ischaemia causes renin excretion, converting Angiotensin I to Angiotensin II, leading to vasoconstriction and aldosterone secretion and subsequent salt and water retention.

MRA is ideal for imaging diagnosis of RAS, however, this is not rebateable by Medicare and therefore not readily available in Australia. Doppler ultrasound measures renal aortic peak systolic velocity ratio, intrarenal artery acceleration time and renal resistive index. As with any ultrasound study, renal Doppler is dependent on patient physique and operator experience. CTA (CT angiogram) has become popular with the availability of very fast multidetector scanners. As little as 50-75 cc of contrast is used to complete the study, and therefore even patients with mild to moderate renal impairment can be scanned safely, especially with renal protection regimens, such as saline/bicarbonate hydration. Renal size discrepancy, cortical thinning and scarring, accessory renal arteries and adrenal lesions are readily detected. CTA is highly sensitive for RAS and therefore good for screening patients with clinical predictors of RAS. Presence of ostial calcification may over or underestimate stenosis. The quality of post processing for CPR (curved planar reformation) is dependent on the skills of radiologists and radiographers. Good CPR is crucial in the accuracy of the CTA and clinicians need to be aware of this and demand this from the imaging centres.

Ostial RAS is usually atherosclerotic and very often coexists with coronary artery and peripheral artery disease. Primary stenting is the standard treatment nowadays. Surgical revascularization is rarely performed. Cure of hypertension is rare with atherosclerotic ostial stenosis. Stenting may improve blood pressure control with a reduced number and lower doses of antihypertensives, and allow usage of ACE inhibitor/angiotensin

blocker without compromising renal function. Stenting in RAS is beneficial in patients with worsening angina or congestive heart failure, by improving the complex physiologic changes such as renin angiotensin aldosterone axis, volume overload and peripheral vascular constriction.

Mid to distal renal artery disease can be due to fibromuscular dysplasia (FMD), typical in a young female hypertensive. FMD has a "string of beads" appearance on CTA and catheter angiogram. This condition is unfortunately under-diagnosed in the community and patients tend to present at a much later age when their blood pressure is more difficult to control. Since angioplasty alone is very effective, with >80-90% improvement and 44% cure rate, timely diagnosis of FMD is very important.

Indications for RAS intervention are listed in Box 3. (PTO)

BOX 3: INDICATIONS FOR RAS INTERVENTION:

• Clinical:

- Accelerated, resistant or malignant hypertension
- Recent onset or progressive moderate to severe renal dysfunction
- Recurrent Pulmonary Edema

• Anatomic:

- Haemodynamic significant stenosis: > 50% diameter or 75% reduction in cross sectional area
- Post-stenotic dilatation
- Diminished renal size: length difference ≥ 1.5 cm; decrease in length ≥ 1 cm



DR EISEN
LIANG

MBBS (Hons 1 NSW)
FRCR (Lond) FRANZCR

Dr Liang is an Interventional Radiologist at SAN Radiology, Sydney Adventist Hospital. He has special interests in peripheral vascular disease, renal artery stenosis, oncology intervention and uterine fibroid embolisation. He is the NSW representative of the Interventional Radiology Society of Australasia. Phone 9487 9840 Fax 9487 9845 Email eisenliang@gmail.com. Website www.sir.net.au.

San RADIOLOGY **UPDATE**
**RENAL ARTERY STENOSIS:
 DIAGNOSIS AND
 INTERVENTION**

CONTINUED FROM PAGE 1

by Dr Eisen Liang

For an individual patient, there are other factors that need to be considered, such as level of blood pressure control medically, tolerance and compliance to antihypertensive therapy, renal function, evidence of progressive nephron loss and co-morbid medical condition (heart failure, angina) and anticipated ease of procedure.

Using modern techniques, renal artery intervention is a safe procedure with very low complication rate. The reported major complication rate in the literature is 2 - 3 % (30 day mortality < 1%, nephrectomy < 1%, worsening of chronic renal failure 2%,

systemic embolization 3%). The author's series of 88 interventions and 100 stents (January 2005 to March 2009) had no major complication, and 3 minor access site complications that did not require specific treatments.

A CASE STUDY:

A 71 y/o male, who had a previous left nephrectomy for RCC, had difficult to control hypertension and rising creatinine 150 to 260. A renal duplex ultrasound of right renal artery showed > 60% stenosis, while a CTA showed 80-90% stenosis (fig 1a and 1b). He developed flash pulmonary edema triggered

with 300 cc of intravenous fluid hydration for the CTA. A right renal artery stenting was performed (fig 2a and 2b). At 6 and 12 month follow-ups, his blood pressure was well controlled, Cr is stable at 145 and there has been no recurrence of pulmonary edema.

REFERENCE:

Journal of Vascular Interventional Radiology
 Volume 21, Issue 4, Pages 421 - 430 (April 2010)
Quality Improvement Guidelines for Angiography, Angioplasty, and Stent Placement for the Diagnosis and Treatment of Renal Artery Stenosis in Adults

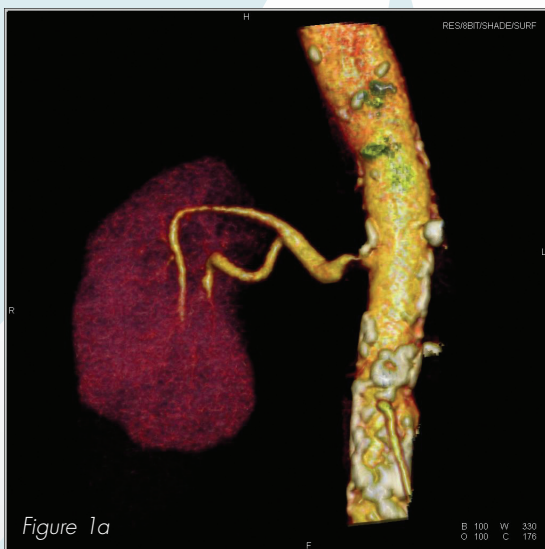

Figure 1a

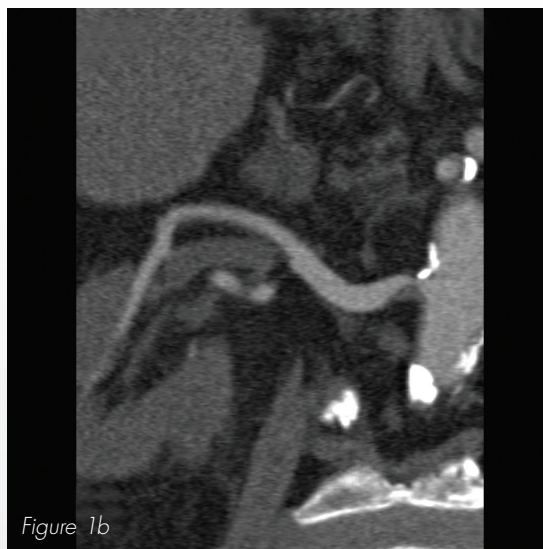

Figure 1b

Fig 1a A CTA surface shaded display showing a tight stenosis at the right renal artery ostium.

Fig 1b A CTA curved planar reformation showing a tight stenosis at the right renal artery ostium.

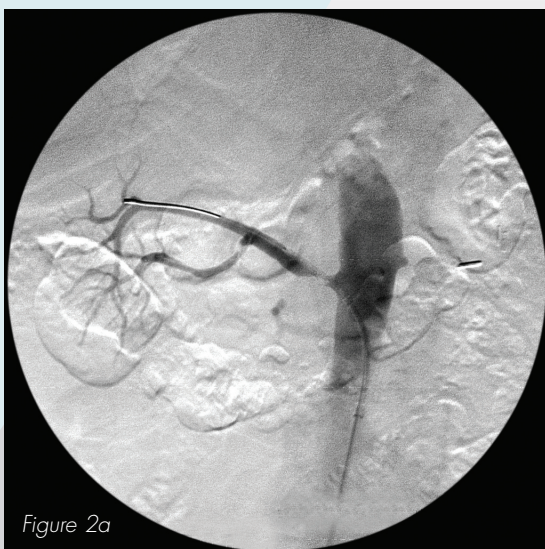


Figure 2a

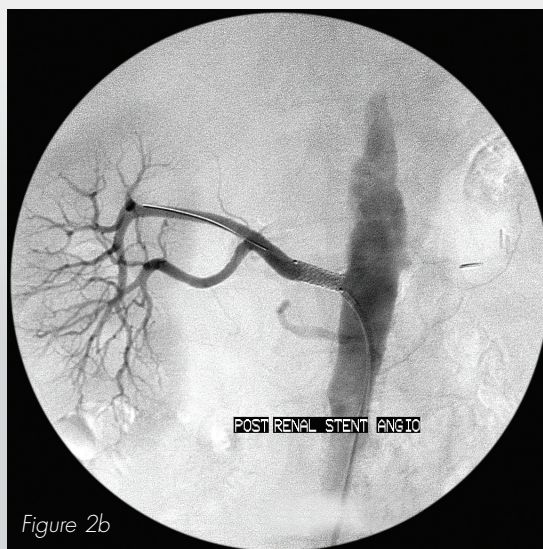


Figure 2b

Fig 2a Angiogram showing good correlation with CTA.

Fig 2b Post stenting angiogram